

COMPLETE CONGENITAL HEART BLOCK IN A NEWBORN ASSOCIATED WITH MATERNAL SYSTEMIC LUPUS ERYTHEMATOSUS: A CASE REPORT

Haile Gilcha, MD¹, Solyana Henok²

ABSTRACT

BACKGROUND: Complete Congenital Heart Block (CCHB) is an uncommon life-threatening disease of the newborn which leads to significant neonatal morbidity and mortality. It is usually diagnosed early in life and highly associated with maternal autoimmune and connective tissue disorders. CCHB frequently presents with bradycardia which can be diagnosed by fetal electrocardiogram.

RESULTS: This is a case report of a male neonate born with a third-degree heart block to a mother with high Ro/SSA titer.

CONCLUSION: Neonates born to women with SLE have an increased risk of CHD, and an increased risk of having a CHD repair procedure later. It is important to diagnose, treat or refer neonates with CCHB early for definite management with pacemaker insertion as it helps for a better prognosis and prevention of associated complications, but this is not often possible in low resource settings like Ethiopia.

KEYWORDS: Congenital Heart Block, Systemic Lupus Erythematosus, Bradycardia, SS-A/Ro Antibodies

(The Ethiopian Journal of Reproductive Health; 2023; 15; 56-60)

1 Department of Obstetrics and Gynecology, Myungsung Christian Medical Center, Addis Ababa, Ethiopia

2 Senior Medical Student, Myungsung Medical College, Addis Ababa, Ethiopia

INTRODUCTION

Complete congenital heart block is uncommon and life threatening disorder which is estimated to occur in about 1 in 20,000 live births in the US¹elsewhere its only discussed in case series². It has a poor prognosis especially when associated with congenital heart defects^{1,3}. It commonly results from a transplacental transfer of maternal anti-Ro/SSA and/or Anti-La/SSB antibodies which can have an effect on the fetal heart by provoking fetal conduction disturbances⁴ and in mothers with autoimmune hypothyroidism. The incidence differs among the different anti-bodies; 2% in anti-Ro/SSA positive women, 3% in presence of both anti-Ro/SSA and anti-La/SSB⁵. The risk is much higher if the mother already has a previous child with Neonatal lupus erythematosus or has hypothyroidism due to thyroid autoantibodies that test positive for anti-Ro/SSA antibodies^{1,2}.

THE CASE

A 35 years old GIII AII mother presented to our hospital's Obstetrics OPD for antenatal follow-up 3 years ago at 26 weeks of gestation. She had a history of 2 prior early first trimester spontaneous abortions at 5 weeks and 8 weeks of gestation respectively. 1 year preceding the third pregnancy she was diagnosed with Autoimmune Hypothyroidism (TSH=10.02, Free T3=3, Free T4=1.14, TPHA negative) and was started on Thyroxine 100mcg on 5 days and 150mcg on 2 days per week during workup to know the cause of recurrent miscarriages. She had regular ANC follow-up during the 3rd pregnancy. She has taken prenatal vitamins and 2 doses of TT vaccine. She was told to have dietary and life style modifications after her 2 hours OGTT (FBS=91, 2 hrs RBS=146), results were consistent with Gestational Diabetes. A third trimester ultrasound at around 6 months of gestation showed a fetal heart beat in the range of 52-60 beats/min with no visible structural heart defect. She had close antenatal monitoring and had an elective

c-section done at 38+6 weeks of gestation for the indication of severe fetal bradycardia secondary to ?conduction defects. She delivered a male neonate weighing 3700 gm with an APGAR score of 8 and 9 at the 1st and 5th minute respectively. Post delivery baby didn't need NICU admission, was stable with a heart rate of 58-60 beats/min and was by mother's side. Upon discharge baby was referred to a pediatrics cardiac center where the pertinent finding from investigations done was on ECG (Fig 1) and echocardiography which showed a complete heart block and Echocardiography revealed a small PDA 3-5mm, with moderate MR and mild TR. As part of workup for the cause of the congenital heart block maternal anti-Ro and anti-La antibodies were sent abroad which showed a higher value for the first. The baby had close monitoring at a pediatrics cardiac center and had a permanent pacemaker insertion and PDA ligation done at the age of 1 year.

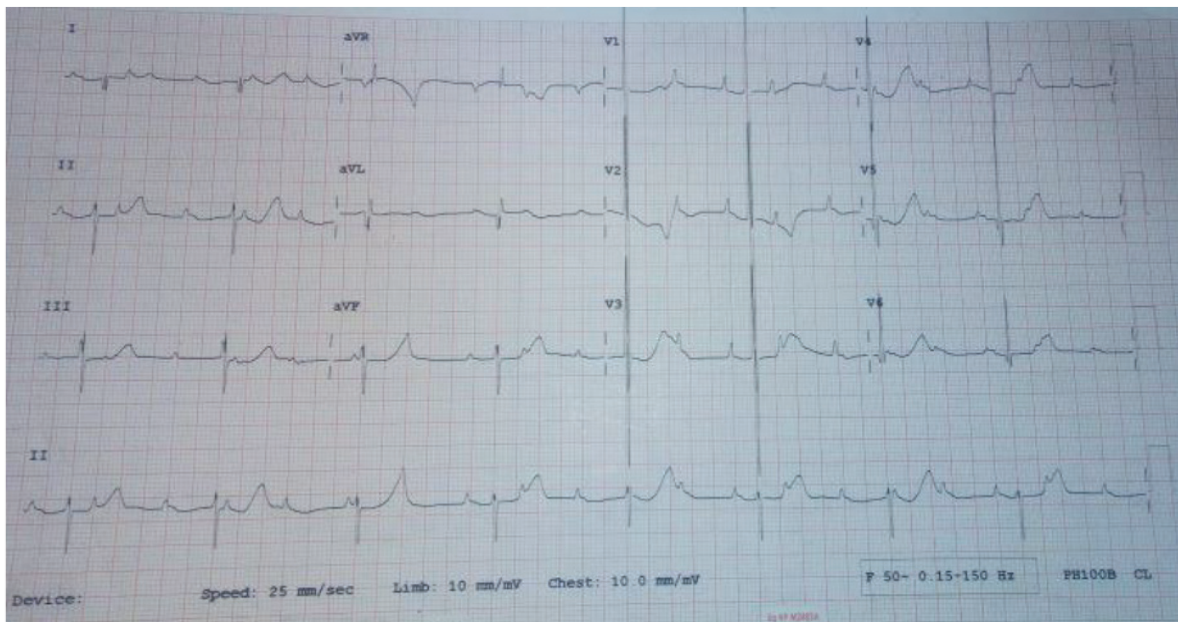


Figure 1: ECG showing a 3rd degree AV block

Complete congenital heart block is a potentially fatal condition usually occurring in association with autoimmune antibodies in the mother that cross the placenta and lead to conduction defects by involving the atrioventricular tissues of the fetal heart due to inflammatory changes or by interfering with the ion channel leading to fibrosis^{5,6}. Fetal congenital heart block (CHB) is the most common outcome of pregnancies related to Systemic Lupus Erythematosus; SLE. It is systemic autoimmune disease, with multisystemic involvement in which the clinical manifestations are exaggerated during pregnancy due to high levels of estrogen⁶. Anti-nuclear antibody (ANA) is the most sensitive antibody, and anti-ds DNA antibodies and anti-smith antibodies are more specific for the diagnosis of SLE³. There are also non-specific antibody subtypes targeted against nuclear material like antibodies to Ro (SSA) and La (SSB). Our patient had remarkable history of multiple spontaneous abortions, autoimmune hypothyroidism in the past and was diagnosed with high levels of anti-Ro antibody which both go for SLE.

Congenital heart block can be identified in utero between 18 and 28 weeks of gestation during routine antenatal checkups and evaluating by fetal echocardiography for the presence of fetal bradycardia can help detect ongoing conduction defects and complications like hydrops fetalis(1). Antenatal visit at 24 weeks in our patient revealed fetal bradycardia ranging from 52-60 beats per minute which prompted an assessment with fetal echocardiography which confirmed the diagnosis of complete heart block in the fetus. Unlike many reported cases of CCHB with concomitant heart defects, no major structural heart defect was detected antenatal in our case.

If diagnosed in utero in a mother who tested positive for SLE autoantibodies, management mainly comprises organized and timely monitoring for heart block and treating the first known heart block with steroids, sympathomimetics, plasmapheresis and fetal pacing depending on the degree of block³. In our case the diagnosis of maternal lupus was made postnatal so no management was initiated during pregnancy and she delivered a healthy child at term.

Early pacemaker insertion for children presenting with symptoms during the neonatal period helps to prevent a sudden cardiac death and improve the quality of life^{3,6}. In our case pacemaker insertion was delayed until 1 year after birth since the baby was stable and had no complication.. The patient is now on regular follow-up with a pediatric cardiothoracic surgeon.

CONCLUSION

Pregnancy associated with SLE is rare and may be complicated by severe outcomes. Fetal complete heart block is one of the most commonly encountered outcomes and is diagnosed with the help of a fetal echocardiogram. Patients who are at high risk of developing CHB warrant a frequent surveillance at 2nd trimester because initiation of steroids may improve outcome. The delivery should be planned in a tertiary care centre where pacemaker placement facility is available, when needed. Because there are only very few studies available, the authors recommend more studies to be done on the importance of steroid initiation on improving outcome of complete congenital heart block.

CORRESPONDING AUTHOR:

Solyana Henok
Senior Medical Student, Myungung Medical
College, Addis Ababa, Ethiopia

REFERENCES

1. Kiblawi MA, Naeem A, Al Attrash EA, Kar S, Goud BKM. Complete Congenital Heart Block in a Newborn Associated with Maternal Systemic Lupus Erythematosus: A Case Report. *Int J Med Students*. 2013;1(3):128-31.
2. Lun Hon K, Leung AKC. Neonatal lupus erythematosus. *Autoimmune Dis*. 2012;1(1).
3. Pallangyo P, Mawenya I, Nicholaus P, Mayala H, Kalombola A, Sharau G, et al. Isolated congenital complete heart block in a five-year-old seronegative girl born to a woman seropositive for human immunodeficiency virus: A case report. Vol. 10, *Journal of Medical Case Reports*. 2016.
4. Roche B, Lhote F, Chasseray JE, Godefroy Y, Meyer O, Leon A, et al. Fetal congenital heart block and maternal systemic lupus erythematosus: Can plasma exchanges play a useful role? Vol. 13, *Transfusion Science*. 1992. p. 463-6.
5. *Frontiers Autoimmune Congenital Heart Block A Review of Biomarkers and Management of Pregnancy Pediatrics*.
6. Khan S, Anvekar P, Lohana P, Sheeraz Alam M, Ali SR. Fetal Congenital Heart Block Associated With Maternal Primary Systemic Lupus Erythematosus and Sjogren's Syndrome. *Cureus*. 2021.
7. Breur JMPJ, Visser GHA, Kruize AA, Stoutenbeek P, Meijboom EJ. Treatment of fetal heart block with maternal steroid therapy: Case report and review of the literature. Vol. 24, *Ultrasound in Obstetrics and Gynecology*. 2004. p. 467-72.